



ORIGINAL ARTICLE

Coronary vein defibrillator coil placement in patients with high defibrillation thresholds

Moisés Rodríguez-Mañero MD, PhD^{1,2,3,4}  | Bahij Kreidieh MD¹ | Sergio H. Ibarra-Cortez MD¹ | Paulino Álvarez MD¹ | Paul Schurmann MD¹ | Amish S. Dave MD, PhD¹ | Miguel Valderrábano MD^{1*} 

¹Methodist DeBakey Heart and Vascular Center and Methodist Hospital Research Institute, The Methodist Hospital, Houston, Texas

²Cardiology Department, Complejo Hospital Universitario de Santiago, Santiago de Compostela, Spain

³IDIS (Instituto para el Desarrollo e Integración de la Salud), Santiago de Compostela, Spain

⁴CIBERCV (Centro de Investigación Biomédica en Red de Enfermedades Cardiovasculares), Santiago de Compostela, Spain

Correspondence

Miguel Valderrábano, Division of Cardiac Electrophysiology, Department of Cardiology Houston Methodist Hospital, Houston, TX.
Email: mvalderrabano@houstonmethodist.org

Abstract

Background: Elevated defibrillation threshold (DFT) occurs in 2%-6% of patients undergoing implantable cardioverter defibrillator (ICD) implantation. Adding a defibrillation coil in the coronary sinus (CS) or its branches can result in substantial reductions in the mean DFT. However, data regarding acute success and long-term stability remain lacking. We report our experience with this bailout strategy.

Methods: Patients with elevated DFT at implantation (safety margin at implantation <10 J) and those with failed ICD shocks for ventricular arrhythmias (VA) referred for high DFT underwent placement of an additional defibrillation coil in the CS. DFT testing was performed at the completion of the implantation procedure. External potentially reversible factors were excluded. High-output devices were systematically used.

Results: Four patients with high DFT at implantation and two with several failed shock attempts underwent placement of a defibrillation coil in the CS. Mean age was 41.8 (23-78). They presented a mean LVEF of 21% (15-30), QRS-complex duration of 109.8 milliseconds (87-168), body surface area of 1.96 m² (1.45-2.58), and a mean R wave of 16.3 mV (8-27). Defibrillation coil implantation in the CS (final shocking configuration of right ventricle as anode and left ventricle (LV) plus can as cathode) was associated with successful DFT testing in all. Three patients had a concomitant LV lead for biventricular pacing. During a mean follow-up of 54.67 months (10-118), two patients experienced successful ICD shocks for VA (one of them also presented inappropriate shocks because of the fast conducting atrial fibrillation).

Conclusions: Positioning of a defibrillation coil in the CS can result in a substantial reduction in mean DFT and associates with optimal long-term stability.

KEYWORDS

coronary sinus coil, defibrillation thresholds, implantable cardioverter defibrillator, sudden cardiac death, ventricular arrhythmia

1 | INTRODUCTION

The implantable cardioverter defibrillator (ICD) prevents arrhythmic death, both through primary and secondary prevention.¹ Its efficacy and reliability have substantially improved over the past 30 years. Refinements since its development include the generator serving as an active electrode, several lead refinements, and higher energy output.² Nevertheless, its effectiveness in ventricular arrhythmia (VA) conversion is not faultless. High defibrillation threshold (DFT) is still a clinical problem in 2%-6% of ICD implants.³ Likewise, postmortem interrogation of ICDs revealed that 25% of sudden deaths in ICD patients were caused by failure to defibrillate ventricular fibrillation (VF).⁴ Bailout alternatives have been proposed in this setting. Such strategies include reassessment of the right ventricular (RV) lead position,⁵ alteration of the shock waveform,^{6,7} implantation of subcutaneous arrays,⁸ independent positioning of the proximal coil of a dual-coil system in the left subclavian vein⁹, or placement of epicardial patches.¹⁰ Placement of a coil into the coronary sinus (CS) lead can also result in substantial reductions in the mean DFT. However, data regarding acute success and long-term stability remain lacking.

This study sought to report a single tertiary center's experience with CS coil implantation to help establish a safety margin for defibrillation.

2 | METHODS

2.1 | Data collection

Of the 1546 patients who underwent ICD/CRT-D implantation between 12/2006 and 11/2012, six patients (0.3%) were considered appropriate candidates for placement of a coil into the CS since their ICD had failed to defibrillate at maximal output in at least one of two attempts. Patients in whom an initial high DFT had been successfully addressed by either ICD programming (waveform tuning or turning SVC coil off-on)¹¹ or repositioning the RV coil were excluded, as were patients with clinical contraindications to DFT testing. Patients provided informed consent, including agreement to the unconventional lead positioning. Data were collected as part of an IRB-approved protocol. This data consisted of patient characteristics including age, gender, comorbid conditions, prior surgeries/procedures, and implanted devices. Procedural logs and images were extracted and analyzed for complications and relevant time intervals. In addition, follow-up times, ICD intracardiac recordings, and clinical outcomes were documented retrospectively from hospital records.

2.2 | Implantation

Standard transvenous ICD and CRT-D implantation were implemented. For the purpose of defibrillation coil positioning into the CS, a venogram of the CS was systematically performed in order to assess the presence of a ventricular branch with a sufficiently large diameter for cannulation. Subsequently, a sheath was placed, and through it, a wire (Wholey, Covidien, Plymouth, MN, USA) was

advanced into the selected ventricular vein through a CS sheath. The sheath was advanced into the ventricular vein branch of choice so that its tip would be committed to the vein. We then advanced an ICD coil in the vein. This lead was connected to the proximal DF-1 port of the ICD. Finally, upper limit of vulnerability testing was conducted again.

2.3 | DFT testing

Ventricular fibrillation was induced via delivery of a 0.8 or 1 J T-wave shock. Upon detection of VF, a defibrillation shock of 25 J was delivered. If this shock failed to terminate VF, 25-35 J was delivered. Successful defibrillation was documented upon termination of VF with the implanted device.

2.4 | Clinical follow-up

As a standard precautionary measure, all patients were hospitalized for at least 24-hours postimplantation. They underwent continuous telemetry monitoring, a 12-lead electrocardiogram, and a 24-hour ambulatory electrocardiography prior to discharge from the hospital. In the absence of symptoms or device therapy, patients were seen routinely every 3-6 months for clinical review and device interrogation. ICD information was retrieved through the device interrogation.

2.5 | Statistical analysis

Gaussian continuous variables are reported as mean \pm SD and non-Gaussian variables as Median [minimum-maximum]. Qualitative findings were described as numbers and percentages. All statistics were performed with the use of the SPSS software (SPSS v19, Armonk, NY, USA). All authors had full access to the data and take responsibility for its integrity. They have read and agreed to the manuscript as written.

3 | RESULTS

Defibrillation threshold testing was performed in 96% of all patients referred for ICD implantation in a single tertiary center over a 6 year interval (Table 1 and Figures 1 and 2, respectively). A total of six patients underwent ICD lead placement in the CS. Five patients were male, and mean age was 41.8 years (23-78). They presented a mean LVEF of 21% (15-30), mean QRS-complex duration of 109.8 milliseconds (87-168), mean body surface area of 1.96 m² (1.45-2.58), and a mean RV wave amplitude upon implantation of 16.3 mV (8-27). Five patients had nonischemic heart disease while one suffered from ischemic cardiomyopathy.

Of these, four patients presented with high DFT at implant despite polarity wave changes, tilt modifications, and more apical RV lead positioning (patients number 1-4 from Table 1). Analysis of intracardiac recordings in these cases revealed no undersensing during

TABLE 1 Baseline characteristics and outcomes of patients with a coronary sinus lead implanted to help establish a safety margin for defibrillation

Patient	Age	Gender	Origin	LVEF (%)	BSA (m ²)	Procedure Duration (min)	QRS (ms)	R wave (mV)	Fluoro time (min)	Reason for CS Implantation	Final defibrillation threshold (Joules)	Follow-up (months)/events
Number 1 (Figure 1A)	46	F	NICM	30-34	1.45	178	110	15.1	21.50	Failed defibrillation while testing leads during implantation, despite polarity change and SVC coil on/off. A coil into the CS was inserted directly	25	46 months/No events
Number 2 (Figure 1B)	33	M	NICM	20-25	1.73	360	100	26.7	12.3	ICD right-sided due to infection on the left sided device. Coil in the left brachiocephalic vein was attempted without success	28	118 months/Two appropriate shock
Number 3 (Figure 1C)	78	M	ICM	20	1.89	286	87	12.4	40.0	Failed defibrillation while testing leads during implantation	25	36 months/No events
Number 4 (Figure 2A)	24	M	NICM	15-20	2.58	175	100	25	15.40	Failed defibrillation while testing leads during implantation	26	104 months/ Multiple appropriate shocks Two inappropriate shocks
Number 5 (Figure 2B)	47	M	NICM	20	2.03	196	168	11.4	30.77	Several failed ICD shocks shock postimplantation	28	14 months/No events
Number 6 (Figure 2C)	23	M	NICM	<20	2.13	250	94	8	24.3	Several failed ICD shocks postimplantation. Attempt to implant a new lead in the RV or LV branch of CS was done without success. Ultimately, a lead into the RV, LV coil, and the original lead SVC coil success	30	10 month/No events

BSA, body surface area; CS, coronary sinus; F, females; ICD, implantable cardioverter defibrillator; LV, left ventricle; LVEF, left ventricular ejection fraction; M, male; RV, right ventricle; SVC, superior vena cava.

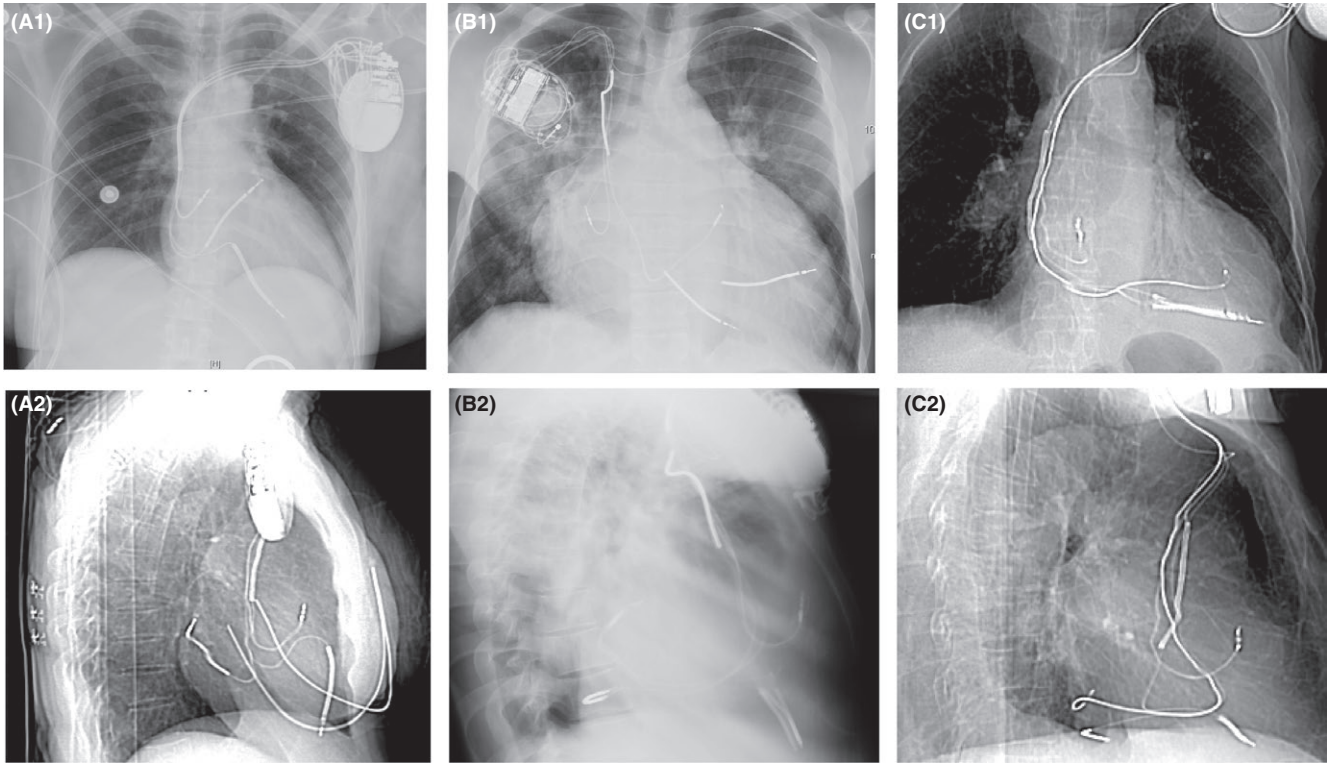


FIGURE 1 Chest radiograph of cases 1-3, respectively, presented in Table 1, showing the final position of the coronary sinus coil. Postero-anterior fluoroscopic view (A1; B1; C1; D1) and lateral fluoroscopic view (A2; B2; C2; D2)

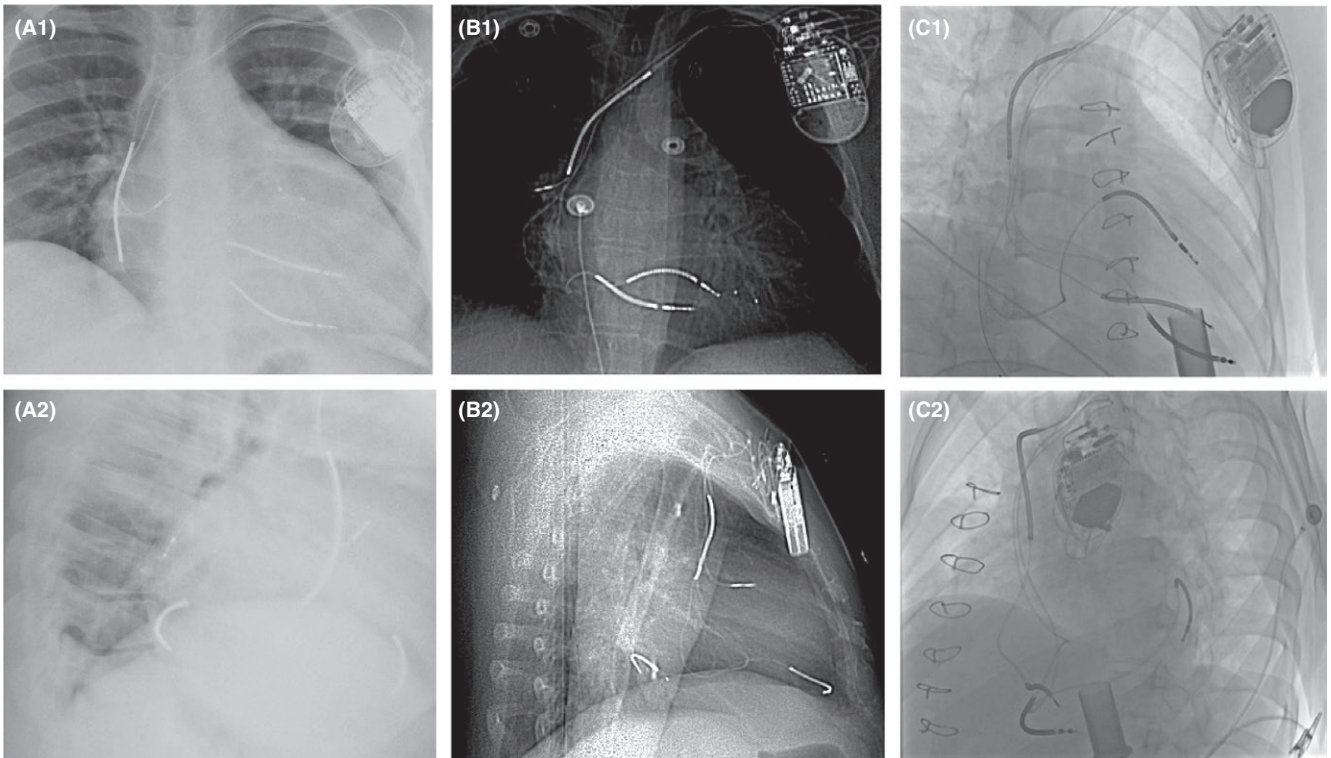


FIGURE 2 Chest radiograph of cases 4-6, respectively, presented in Table 1, showing the final position of the coronary sinus coil. Postero-anterior fluoroscopic view (A1; B1; C1; D1) and lateral fluoroscopic view (A2; B2; C2; D2)

VF, and the first shock was delivered unanimously without delay. Two patients underwent simultaneous LV lead implantation in a posterolateral branch of the CS for biventricular pacing (patients 2 and 3, Table 1; Figure 1B,C).

Another two patients (patient 5, Figure 2B and patient 6, Table 1) presented several failed ICD shocks. Patient number 5 had numerous futile ICD shocks despite two previous RV lead insertions. Noninvasive programming changes proved unsuccessful and the patient was brought to the laboratory for revision of his system in order to establish adequate DFT safety margins. In this patient, an ICD lead (after implantation of a LV lead for biventricular pacing) was placed in the CS. Initially, several trials led to shock failure. Ultimately, after several attempts with failed shocks, a final configuration using the RV coil as the anode and CS lead and active can in combination as the cathode repeatedly provided an adequate safety margin for defibrillation (in three separated attempts). Shock impedance was 31 ohms. Patient number 6 (Table 1) also presented several failed ICD shocks 7 years postimplantation. An additional lead implantation into the RV was tried without success. Ultimately, a lead into the RV, a LV coil (Figure 2C), and the original lead SVC coil succeeded with 30 J.

Patient 2 (Table 1), with a right-sided system due to infection of the previous left-sided primo implanted, before the defibrillation coil implantation into the CS, an independent positioning of the proximal coil of a dual-coil system in the left subclavian vein was attempted without success (Figure 1B). Patient 2 was maintained on amiodarone, but dosing did not change following implantation. Patient number 6 was under amiodarone when the event occurred but after the procedure it was replaced by sotalol.

All in all, uneventful implantation of a defibrillation coil in the CS succeeded in all six patients. The active fixation coil was not unscrewed inside the CS in any. A final configuration assigning the RV as anode and the combination of the CS lead and active can as cathode were advocated in all cases.

During a mean follow-up of 54.67 months (10-118), two patients experienced successful ICD shocks for VA (patients 2 and 4, Table 1). Patient 4 also suffered inappropriate shocks because of the atrial fibrillation with rapid ventricular rate. No ICD lead dislodgement, diaphragmatic myopotential oversensing, or interference with the LV pacing lead took place throughout the follow-up period (in the two cases where a LV lead coexisted with the ICD coil). Impedance shock remains unaltered during the follow-up period.

4 | DISCUSSION

The present study demonstrates the efficacy of coil placement within the CS (as part of a dual-coil system) in patients with a high DFT or previously failed ICD shocks. Independent positioning of this coil in the CS can result in substantial reductions in the mean DFT and associates with optimal long-term stability.

4.1 | Pitfalls in currently available techniques

Normal DFT is usually measured at ≤ 15 J and often < 10 J with biphasic shocks and improved lead systems. DFTs above 20 J commonly arise during ICD implantation.¹² Although incidence is reduced with newer high-output devices, there remains a subset of patients in whom adequate safety margins are unrealizable. When an elevated DFT is detected at implant testing or during follow-up, culpable external reversible factors must be considered first. Next, noninvasive programming options are exhausted in efforts to reduce DFT values. These simple alternatives can provide adequate safety margins in most cases.¹³ However, in a small percentage of patients, invasive treatment options are necessary.¹² For this population, multiple alternative methods to lower the DFT have been reported, including the implantation of an extra coil in the superior vena cava (SVC), azygos vein¹⁴, or the use of a subcutaneous array.⁸

Every available alternative offers distinct advantages. However, each has its shortcomings as well, a factor that has precluded the generalizability of a standard bailout protocol. For instance, the addition of a coil in the azygos vein to lower the DFT has been described by a few operators.¹⁴⁻¹⁶ However, it has proven to be highly time-consuming as it requires significant manipulation in order to manoeuvre a stiff defibrillation coil across many angles spanning from the brachiocephalic vein to the distal part of the azygos vein.¹⁵ In previous reports, the use of an azygos coil effectively reduced the DFT to an acceptable level, an effect likely attributable to the addition of an antero-posterior defibrillation vector across the LV. The use of a subcutaneous array, also effective in DFT reduction, requires additional skin incisions or tunneling, which similarly increase the complexity of the procedure.

4.2 | CS coil placement

In theory, placement of a coil in the CS should provide a feasible solution to the aforementioned hurdles. As is the case with azygos vein coil placement, CS placement adds an antero-posterior defibrillation vector across the LV. Moreover, the CS represents a more accessible structure than the azygos vein, one that does not require special equipment and can thus be accomplished expeditiously in the standard implant laboratory. Nevertheless, the technique raises concerns about possible hindrance of LV lead delivery in the event that a cardiac resynchronization therapy (CRT) device is required. In our limited experience, this issue did not represent a significant impediment in three patients who underwent LV lead placement for biventricular pacing simultaneously with the ICD coil implantation. Another plausible concern is contact between the CS coil and the LV lead, which may result in oversensing and inappropriate shocks. In our small cohort, the coil was consistently delivered out of contact with the LV lead, and no inappropriate shocks due to oversensing or interference with the LV lead ever took place. Although it would have been attractive to use the defibrillation lead in the LV vein to pace the LV and minimize the hardware deployed in the CS, adequate LV capture was not achieved, and a separate lead was required for cardiac resynchronization.

Frequent ICD discharges may result in a secondary rise in DFT because of the fibrosis around the electrode tip.^{17,18} Despite multiple appropriate and inappropriate shocks within our cohort, no significant rise in DFT was noted on follow-up. Amiodarone treatment is also known to increase DFT slightly,¹⁹ two patients in our cohort received amiodarone and there was no change in dosage following implantation in one of them. Finally, lead extraction is often a difficult task, one that none of our patients have required so far. Subsequently, it remains to be seen whether an additional lead-array could be beneficial in the event of system extraction.

All in all, from our limited experience, the dual-coil system with CS lead appears to be a safe and reliable bailout strategy. Nevertheless, further studies with longer follow-up and larger patient cohorts are mandated in the establishment and widespread adoption of this technique.

4.3 | Limitations

The necessity and appropriateness of DFT testing often comes into question. Complications of DFT testing relate to: (a) prolonged VF when shocks fail, leading to myocardial ischemia and contractile dysfunction that can persist even after restoration of normal rhythm, particularly in preexisting CHF, and (b) direct electroporation damage to the myocardium due to repeated shocks. Both can lead to electromechanical dissociation and contractility dysfunction, and culminate in cardiogenic shock. This study does not attempt to confirm the efficacy of DFT testing as an appropriate tool in the optimization of ICD shocks. Rather, the study seeks to report on the feasibility of a bailout strategy for both patients with high DFT and those with failed ICD shocks. Nevertheless, multiple limitations in this study merit discussion. The study was retrospective and is subject to the inherent limitations of this study design. In addition, study results were based on a relatively small number of cases with a limited follow-up period. Moreover, the study design lacks a randomized control group consisting of patients undergoing alternative bailout strategies. Finally, another important disadvantage of this approach is that the lead needs to be connected to the proximal DF-1 port of the ICD, with the subsequent discomfort for patient and operator as compared with the DF-4 connector.

The study must thus be regarded as a proof of the feasibility of a novel strategic approach. Its generalizability and widespread applicability must be assessed further in larger, systematic trials. Moreover, until the safety of extraction can be established, this technique is probably best reserved for patients who may have very advanced disease and lack of other option.

5 | CONCLUSION

Positioning of a defibrillation coil into the CS in patients with elevated DFT and those with failed ICD shocks is a feasible alternative, which can result in a substantial reduction in mean DFT and it is associated with optimal long-term stability.

ACKNOWLEDGEMENTS

Dr. Moisés Rodríguez-Mañero is the holder of an unconditional grant from Antonio Pacifico, MD fellowship support.

CONFLICT OF INTEREST

Authors declare no conflict of interests for this article.

ORCID

Moisés Rodríguez-Mañero  <http://orcid.org/0000-0001-7566-9321>

Miguel Valderrábano  <http://orcid.org/0000-0002-8401-1684>

REFERENCES

- Connolly SJ, Hallstrom AP, Cappato R, et al. Meta-analysis of the implantable cardioverter defibrillator secondary prevention trials. AVID, CASH and CIDS studies. Antiarrhythmics vs Implantable Defibrillator study. Cardiac Arrest Study Hamburg. Canadian Implantable Defibrillator Study. Eur Heart J. 2000;21(24):2071–8.
- Natale A, Sra J, Axtell K, et al. Preliminary experience with a hybrid nonthoracotomy defibrillating system that includes a biphasic device: comparison with a standard monophasic device using the same lead system. J Am Coll Cardiol. 1994;24(2):406–12.
- Lin EF, Dalal D, Cheng A, et al. Predictors of high defibrillation threshold in the modern era. Pacing Clin Electrophysiol. 2013;36(2):231–7.
- Mitchell LB, Pineda EA, Titus JL, Bartosch PM, Benditt DG. Sudden death in patients with implantable cardioverter defibrillators: the importance of post-shock electromechanical dissociation. J Am Coll Cardiol. 2002;39(8):1323–8.
- Aguel F, Eason JC, Trayanova NA, Siekas G, Fishler MG. Impact of transvenous lead position on active-can ICD defibrillation: a computer simulation study. Pacing Clin Electrophysiol. 1999;22(1 Pt 2):158–64.
- Mouchawar G, Kroll M, Val-Mejias JE, et al. ICD waveform optimization: a randomized, prospective, pair-sampled multicenter study. Pacing Clin Electrophysiol. 2000;23(11 Pt 2):1992–5.
- Kroll MW, Efimov IR, Tchou PJ. Present understanding of shock polarity for internal defibrillation: the obvious and non-obvious clinical implications. Pacing Clin Electrophysiol. 2006;29(8):885–91.
- Avitall B, Oza SR, Gonzalez R, Avery R. Subcutaneous array to transvenous proximal coil defibrillation as a solution to high defibrillation thresholds with implantable cardioverter defibrillator distal coil failure. J Cardiovasc Electrophysiol. 2003;14(3):314–5.
- Markewitz A, Kaulbach H, Mattke S, et al. Influence of anodal electrode position on transvenous defibrillation efficacy in humans: a prospective randomized comparison. Pacing Clin Electrophysiol. 1997;20(9 Pt 1):2193–9.
- Obadia JF, Kirkorian G, Rescigno G, el Farra M, Chassignolle JF, Touboul P. Thoracoscopic approach to implantable cardioverter defibrillator patch electrode implantation. Pacing Clin Electrophysiol. 1996;19(6):955–9.
- Gold M, Val-Mejias J, Leman RB, et al. Optimization of superior vena cava coil position and usage for transvenous defibrillation. Heart Rhythm. 2008;5(3):394–9.
- Russo AM, Chung MK. Is defibrillation testing necessary for implantable transvenous defibrillators?: defibrillation testing is necessary at the time of implantable cardioverter defibrillator implantation. Circ Arrhythm Electrophysiol. 2014;7(2):337–46.

13. Russo AM, Sauer W, Gerstenfeld EP, et al. Defibrillation threshold testing: is it really necessary at the time of implantable cardioverter-defibrillator insertion? *Heart Rhythm*. 2005;2(5):456–61.
14. Cesario D, Bhargava M, Valderrabano M, Fonarow GC, Wilkoff B, Shivkumar K. Azygos vein lead implantation: a novel adjunctive technique for implantable cardioverter defibrillator placement. *J Cardiovasc Electrophysiol*. 2004;15(7):780–3.
15. Seow SC, Tolentino CS, Zhao J, Lim TW. Azygous vein coil lowers defibrillation threshold in patients with high defibrillation threshold. *Europace*. 2011;13(6):825–8.
16. Cooper JA, Latacha MP, Soto GE, et al. The azygos defibrillator lead for elevated defibrillation thresholds: implant technique, lead stability, and patient series. *Pacing Clin Electrophysiol*. 2008;31(11):1405–10.
17. Martin DT, John R, Venditti FJ Jr. Increase in defibrillation threshold in non-thoracotomy implantable defibrillators using a biphasic waveform. *Am J Cardiol*. 1995;76(4):263–6.
18. Epstein AE, Kay GN, Plumb VJ, Dailey SM, Anderson PG. Gross and microscopic pathological changes associated with nonthoracotomy implantable defibrillator leads. *Circulation*. 1998;98(15):1517–24.
19. Zhou L, Chen BP, Kluger J, Fan C, Chow MS. Effects of amiodarone and its active metabolite desethylamiodarone on the ventricular defibrillation threshold. *J Am Coll Cardiol*. 1998;31(7):1672–8.

How to cite this article: Rodríguez-Mañero M, Kreidieh B, Ibarra-Cortez SH, et al. Coronary vein defibrillator coil placement in patients with high defibrillation thresholds. *J Arrhythmia*. 2019;35:79–85. <https://doi.org/10.1002/joa3.12136>