

How to perform EUS-guided tattooing?

Mihai Rimbaş^{1,2}, Alberto Larghi^{2,3}, Pietro Fusaroli⁴, Yi Dong⁵, Stephan Hollerbach⁶, Christian Jenssen⁷, Adrian Săftoiu⁸, Anand V Sahai⁹, Bertrand Napoleon¹⁰, Paolo Giorgio Arcidiacono¹¹, Barbara Braden¹², Sean Burmeister¹³, Silvia Carrara¹⁴, Xin Wu Cui¹⁵, Michael Hocke¹⁶, Julio Iglesias-Garcia¹⁷, Masayuki Kitano¹⁸, Kofi W Oppong¹⁹, Siyu Sun²⁰, Milena Di Leo¹⁴, Maria Chiara Petrone²¹, Anthony Y B Teoh²¹, Christoph F Dietrich²²

¹Gastroenterology and Internal Medicine Departments, Colentina Clinical Hospital, Carol Davila University of Medicine, Bucharest, Romania; ²Digestive Endoscopy Unit, Fondazione Policlinico Universitario A. Gemelli IRCCS, Rome, Italy; ³CERTT, Center for Endoscopic Research Therapeutics and Training, Catholic University, Rome, Italy; ⁴Department of Medical and Surgical Sciences, Gastroenterology Unit, University of Bologna/Imola Hospital, Imola, Italy; ⁵Department of Ultrasound, Zhongshan Hospital, Fudan University, Shanghai, China; ⁶Department of Gastroenterology, Allgemeines Krankenhaus Celle, Celle, Germany; ⁷Department of Internal Medicine, Krankenhaus Märkisch-Oderland, Strausberg and Brandenburg Institute for Clinical Ultrasound, Neuruppin, Germany; ⁸Department of Gastroenterology, Research Center of Gastroenterology and Hepatology, University of Medicine and Pharmacy of Craiova, Craiova, Romania; ⁹Center Hospitalier de l'Université de Montréal, Montreal, Canada; ¹⁰Digestive Endoscopy Unit, Hopital Privé J Mermoz Ramsay Générale de Santé, Lyon, France; ¹¹Pancreatico/Biliary Endoscopy & Endosonography Division, Pancreas Translational & Clinical Research Center, San Raffaele Scientific Institute, Vita Salute San Raffaele University, Milan, Italy; ¹²Johann Wolfgang Goethe University, Frankfurt, Germany & Translational Gastroenterology Unit, John Radcliffe Hospital, Oxford, UK; ¹³Surgical Gastroenterology Unit, Groote Schuur Hospital, Cape Town, South Africa; ¹⁴Digestive Endoscopy Unit, Division of Gastroenterology, Humanitas Clinical and Research Center, Milan, Italy; ¹⁵Department of Medical Ultrasound, Tongji Hospital, Tongji Medical College, Huazhong University of Science and Technology, Wuhan, Hubei Province, China; ¹⁶Medical Department, Helios Klinikum, Meiningen, Germany; ¹⁷Department of Gastroenterology and Hepatology, Health Research Institute of Santiago de Compostela (IDIS), University Hospital of Santiago de Compostela, Santiago de Compostela, Spain; ¹⁸Second Department of Internal Medicine, Wakayama Medical University, Wakayama, Japan; ¹⁹HPB Unit, Freeman Hospital, Newcastle upon Tyne, UK; ²⁰Department of Gastroenterology, ShengJing Hospital of China Medical University, Shenyang, Liaoning Province, China; ²¹Department of Surgery, The Chinese University of Hong Kong, Hong Kong, China; ²²Department Allgemeine Innere Medizin, Kliniken Hirslanden, Beau Site, Salem und Permanence, Bern, Switzerland

ABSTRACT

Recently, we introduced a series of papers describing on how to perform certain techniques and controversies in EUS. In the first paper, “What should be known before performing EUS examinations, Part I,” the authors discussed clinical information and whether other imaging modalities should be needed before embarking in EUS examination. In Part II, some technical controversies on how EUS is performed are discussed from different points of view by providing the relevant available evidence. Herewith, we describe on how to perform EUS-guided fine needle tattooing (FNT) in daily practice. The aim of this paper is to discuss pros and cons for several issues including historical remarks, injecting material, technical approach, and how to perform EUS-FNT including argues in favor and against.

Key words: EUS, India ink, neuroendocrine neoplasms, pancreatic, pancreatic solid tumors, tattooing

This is an open access journal, and articles are distributed under the terms of the Creative Commons Attribution-NonCommercial-ShareAlike 4.0 License, which allows others to remix, tweak, and build upon the work non-commercially, as long as appropriate credit is given and the new creations are licensed under the identical terms.

For reprints contact: reprints@medknow.com

How to cite this article: Rimbaş M, Larghi A, Fusaroli P, Dong Y, Hollerbach S, Jenssen C, *et al.* How to perform EUS-guided tattooing? *Endosc Ultrasound* 2020;9:291-7.

Access this article online

Quick Response Code:



Website:

www.eusjournal.com

DOI:

10.4103/eus.eus_44_20

Address for correspondence

Dr. Mihai Rimbaş, Department of Gastroenterology, Colentina Clinical Hospital, Department of Internal Medicine, Carol Davila University of Medicine 19-21 Stefan cel Mare Street, 020125, Bucharest, Romania.

E-mail: mihai.rimbasm@umfcd.ro

Received: 2020-04-10; **Accepted:** 2020-06-08; **Published online:** 2020-09-02

INTRODUCTION

Recently, we introduced a series of papers describing on how to perform certain techniques,^[1-5] controversies in EUS, and “what should be known before performing EUS examinations.”

In Part I, the authors discussed clinical information and whether other imaging modalities should be needed before embarking in EUS examination.^[6] The content includes the “nihilistic” or “puristic” approach, “I need nothing before EUS” *versus* the clinical approach (“Performing EUS as a clinician, I prefer to review as much clinical data as possible before EUS”. Should transcutaneous ultrasound and EUS be performed by the same operator? The use of esophagogastroduodenoscopy [EGD] before EUS. Should consenting for EUS differ from consenting for EGD? The utility of coagulation tests before EUS and interventions).

In Part II, some technical controversies on how EUS is performed are discussed from different points of view by providing the relevant available evidence.^[7] Does equipment design influence the complication rate? Should we have a standardized screen orientation? Radial *versus* longitudinal (linear) echoendoscopes. Should we search for incidental findings using EUS?

Herewith, we describe on how to perform EUS-guided fine needle tattooing (EUS-FNT) in daily practice. The aim of this paper is to discuss pros and cons for several issues including historical remarks, injecting material, technical approach, and how to perform EUS-FNT including argues in favor and against.

The authors declare that this paper is not intended as a guideline, but rather an opportunity to document the current practice, allowing readers to evaluate their own EUS procedures and to stimulate further discussion.

EUS-GUIDED TATTOOING

Historical remarks

Tattooing has been widely used in luminal endoscopy by injecting India ink or sterile carbon particles into the submucosa of the gastrointestinal tract adjacent to neoplastic lesions, to favor their recognition during subsequent surgery or to facilitate the identification of prior endoscopically resected areas during follow-up

endoscopic examinations. In 2002, the utilization of EUS-FNT to help recognition of a pancreatic lesion during surgery has been successfully applied for the first time by Gress *et al.*^[8] The authors performed preoperative EUS-FNT of a 19 mm × 5 mm insulinoma localized at the pancreatic body–tail junction, in between the splenic vein and the splenic artery. Four milliliters of diluted, filtered, and presterilized India ink solution (Permark Inc., Edison, NJ, USA) was injected at the center of the lesion utilizing a standard 22-gauge fine needle aspiration (FNA) needle.^[8] This procedure was performed at the surgeon’s request to obtain the best possible preoperative localization in an attempt to allow safe performance of lesion enucleation. EUS-FNT was well tolerated by the patient, the lesion could be visualized at laparotomy performed the same day, but unfortunately, enucleation could not be done and distal pancreatectomy with splenectomy was finally performed.

The increasing use of the laparoscopic approach to surgically resect pancreatic body and tail lesions, in particular, small solid and cystic lesions with high-risk features, has intensified the need for a very precise preoperative localization of the target lesion. Indeed, loss of capability to palpate the pancreas may impair tumor recognition or proper assessment of its position, thus impairing surgical resection with tumor-free margins or conservation of as much viable pancreatic tissue as possible. Moreover, the frequently confusing appearance of the surrounding retroperitoneal fat can render intraoperative ultrasound localization of pancreatic lesions difficult (possible in only 60%–90% of the cases).^[9-11] In one case series, intraoperative identification of the lesion failed in four out of 61 patients (6.5%), for whom re-operation was needed.^[12] Thus, a role for EUS-FNT was foreseen particularly for small tumors, located deeply, or in cases in which the resection was deemed problematic because of the close relationship to local vessels or vicinity to the pancreatic duct.

Review of the literature

Table 1 summarizes all case reports and case series describing the use of EUS-FNT up to now.^[8,13-20] Different techniques and solutions were utilized. After few adverse events (AEs) associated with the use of undiluted improperly sterilized India ink solution were described in the literature,^[21] Ashida *et al.* utilized diluted indocyanine green that was injected using EUS-FNT into the pancreatic capsule located just above

Table 1. Summary of the studies evaluating EUS-guided preoperative marking to guide surgical resection

Author, year	Diagnosis ^a (n)	Number of patients	Number of lesions	Lesion size (median)	Needle gauge	Injected solution	Quantity (median)	Intra-operative recognition	Adverse events
Gress, 2002 ^{CR}	Insulinoma	1	1	19 mm×5 mm	22	India ink	4 mL	Yes	None
Zografos, 2005 ^{CR}	Insulinoma	1	1	9.8 mm×8.2 mm	NR	Methylene blue	1 mL	Yes	None
Ashida, 2006 ^{CR}	NR	1	2	5 mm	22	Diluted indocyanine green	0.5 mL	Yes	None
Farrell, 2009 ^{CR}	IPMN with carcinoma <i>in situ</i>	1	1	5 mm	22	GI Spot [®]	2 mL	Yes	None
Lennon, 2010 ^{RS}	PanNEN (6); MCN (2); PDAC (1); IPMN (1); serous cystadenoma (2); epidermoid cyst (1)	13 [§]	13	8-50 mm (13 mm)	22	GI Spot [®]	1.25-5 mL (3 mL)	100%	None
Newman, 2010 ^{RS}	PanNEN (5); MCN (2); PDAC (2); Serous cystadenoma (1)	10 [§]	10	8-28 mm (13 mm)	22	GI Spot [®]	2-4 mL	100%	None
Rodriguez, 2011 ^{CR}	Insulinoma	1	1	9 mm	NR	GI Spot [®]	NR	Yes	None
Leelasinjaroen, 2014 ^{CR}	Insulinoma	1	1	15.5 mm	22	GI Spot [®]	2 mL	Yes	None
Okuzono, 2016 ^{RS}	PanNEN (1); IPMN (3); SPN (1); PDAC (1)	6	6	7-35 mm (16 mm)	25	Sodium hyaluronate and India ink	0.06-0.1 mL (0.08 mL)	5/6 (83%)	None

^aAll lesions were located in the pancreas, [§]It is possible that some or most of the patients might have been reported in both studies. CR: Case report; RS: Retrospective study; NR: Not reported; IPMN: Intraductal papillary mucinous neoplasm; PanNEN: Pancreatic neuroendocrine neoplasm; MCN: Mucinous cystic neoplasm; PDAC: Pancreatic ductal adenocarcinoma; SPN: Solid pseudopapillary neoplasm.

a 5-mm tumor in the pancreatic tail.^[14] The area was easily recognized by the surgeons at open laparotomy performed the following day, whereas the tumor could not be found by palpation or intraoperative ultrasound.^[14] In another report of a small insulinoma in the pancreatic tail, EUS-FNT by injecting methylene blue was successfully performed after the tumor could not be identified by intraoperative ultrasound at initial laparotomy.^[13]

Farrell and colleagues were the first to report the use of the sterile carbon-based Spot[®] solution (GI Supply, Camp Hill, PA, USA) for EUS-FNT of a very small pancreatic adenocarcinoma located at the level of the pancreatic body, close to the portal vein confluence, to guide laparoscopic resection.^[15] The sterile carbon-based solution was injected into an area of normal pancreatic parenchyma located toward the pancreatic head close to the lesion. Tattooing was, in this case also, the only method to identify the tumor, which made possible a safe and uneventful laparoscopic distal pancreatic resection.

In the first large retrospective study on 30 patients with pancreatic body/tail lesions, 13 underwent preoperative EUS-FNT using a sterile carbon-based solution injected in 0.5-mL increments into the normal pancreatic parenchyma, a few millimeters to the right side of the lesion.^[16] The indications for EUS-FNT were either the small size of the lesion to increase the chance for its intraoperative localization or the presence of indistinct borders in cases of larger lesions to increase the possibility of achieving negative resection margins. The pathologic diagnoses were similar between the groups with and without preoperative EUS-FNT, but the lesion size was significantly smaller in the former (median 1.3 cm *vs.* 4.0 cm, $P = 0.03$).^[16] Importantly, all 13 tattoos were clearly identified intraoperatively despite the mean interval of 20 days (range 1–69) between EUS-FNT and surgical laparoscopic resection, and all these 13 patients had negative surgical resection margins. None of the patients in the EUS-FNT group needed conversion to an open surgery, with the advantage of a significantly shorter mean operative time for laparoscopic distal pancreatectomy in the EUS-FNT

group as compared to no EUS-FNT (128.5 min *vs.* 180 min, $P = 0.02$), with no difference of postoperative AEs between the two groups.^[16]

Leelasinjaroen *et al.* subsequently reported for the first time a case of a deep pancreatic head insulinoma that underwent EUS-FNT to guide its localization and surgical enucleation, which allowed the preservation of the pancreatic duct located posterior to the lesion and avoided pancreaticoduodenectomy.^[19]

Finally, in a retrospective case series of six patients (two of them with lesions located in the pancreatic head), the authors reported the use of a newly developed tool allowing for injection of minuscule amounts of solution.^[20] They used a maximum of 0.1 mL of a viscous solution comprising 4:1 sodium hyaluronate and India ink that was injected while slowly withdrawing the needle, to keep it in a strictly limited area, thus avoiding its leak into the peritoneal cavity or retroperitoneal space. In one of these patients (17%), however, the tattoo could not be identified at surgery, mostly related to the fact that the tattooing solution was injected too deep into the pancreatic parenchyma, which did not allow its recognition on the pancreatic surface.

Injecting material

EUS-FNT has been performed injecting several different types of solutions: India ink, indocyanine green, methylene blue, and GI Spot[®] (GI Supply, Camp Hill, PA, USA),^[8,13-15] which have to be sterile to avoid infectious AEs. The initial solution that was used for EUS-FNT was India ink, which is composed of a variety of fine soot (impure carbon particles resulting from the incomplete combustion of hydrocarbons) in colloidal suspension in water to form a liquid.^[22] However, since some reports of AEs have been described during its use in endoscopy,^[21] it has been largely replaced by other solutions. The most frequently utilized is the GI Spot[®], a purified and sterilized preparation of carbon black, which is internalized by macrophages without determining any inflammation in surrounding tissues.^[20] The advantage of this solution is related to its carbon particle content, which is nondegradable and remains into the tissues indefinitely, thus creating a permanent tattoo. Differently, when indocyanine green or methylene blue dye is used, EUS-FNT has to be performed time-wise as close as possible to surgery, since these dyes are water soluble and cleared by the organism's cleaning mechanisms.

Technical approach

A standard EUS-FNA needle should be used for performing EUS-FNT, which should be of a sufficient size to allow easy injection of the tattooing solution but avoid its dispersion (the 22-gauge has been used in most cases). Before inserting it into the working channel of the echoendoscope, the needle should be preloaded with the solution to eliminate all the air from the needle lumen that, once injected, would obscure the ultrasonographic view. The needle is then inserted inside the target lesion where a small amount of the tattooing solution should be slowly injected inside the lesion or immediately near the tumor borders into the normal parenchyma. The process is done while slowly withdrawing the needle to allow for a small quantity of the ink to be also placed in the subcapsular pancreatic space. Care must be taken not to overinject the tattooing solution since the compound can migrate into the peritoneum or the retroperitoneal space and create major discoloration, which could have a negative impact on the intraoperative lesion localization and consequently surgical resection. For pancreatic body or tail lesions, injection should be performed in the nearby pancreatic parenchyma proximal to the lesion toward the pancreatic head [Figure 1].

How to perform EUS-guided fine needle tattooing Step by step

Once preloaded with the solution to be injected [Figure 2], the needle is inserted into the channel of the echoendoscope. The needle tip should then be advanced into the target lesion or the adjacent parenchyma using a thrust movement as it is done for EUS-FNA. A small amount of solution should be injected until a hyperechoic area appears in the endosonographic image at the level of the needle tip. For lesions that are tattooed inside, injection can be repeated in other spots, if needed, in the same endoscopic session. Injection should be done by slowly retracting the needle while continuing injecting, to leave an inked tract and induce discoloration of the subcapsular pancreatic tissues to help surgeons identify the marked spot. Particular attention should be given to inject only anterior to the Wirsung duct and to avoid injecting outside the gastrointestinal tract into the peritoneal/retroperitoneal space.

Routine pre-EUS coagulation testing and management of anticoagulants/antiplatelet drugs

Prothrombin time, INR, and activated partial thromboplastin time should be checked before the

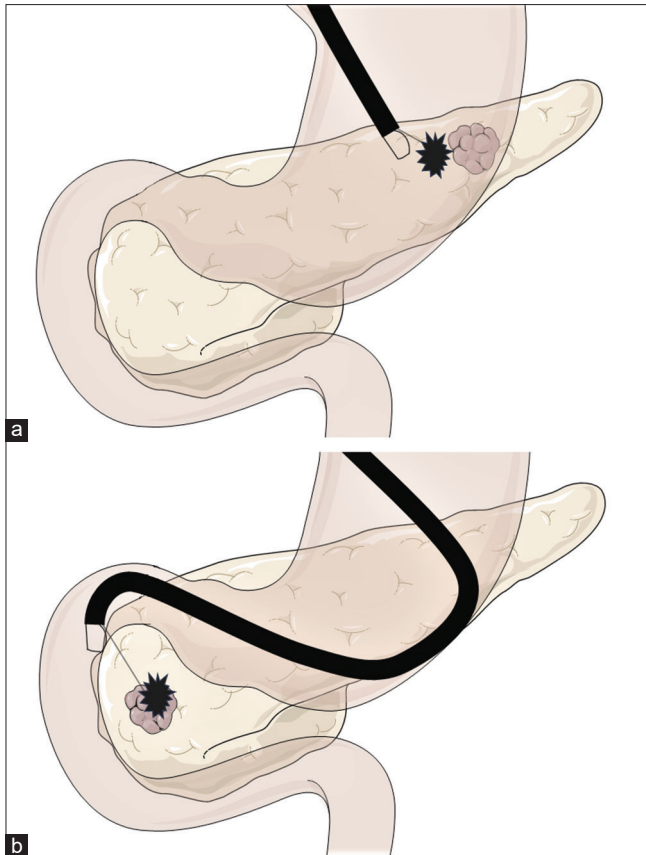


Figure 1. Representative diagram on how to perform EUS-guided tattooing of a pancreatic lesion: (a) Marking of an area of normal pancreatic parenchyma located to the right of a pancreatic body/tail lesion as a landmark for limiting the pancreatic resection with tumor-free margins; (b) Tattooing of a pancreatic head lesion, when the marker is usually injected inside the lesion

procedure equally to a standard EUS-FNA/FNB procedure. Withholding and restarting antiplatelet or anticoagulant treatment periprocedurally should follow the guidelines on the management on anticoagulants/antiplatelet agents for endoscopic procedures, similar to that described for EUS-FNA.^[23,24]

Antibiotic prophylaxis

Once a foreign solution is injected from a nonsterile organ (the upper gastrointestinal tract) into an extraparietal space, broad-spectrum antibiotics, such as ciprofloxacin, second- or third-generation cephalosporins, or clindamycin, should be used prophylactically just before and for 24–72 h after the procedure,^[15,16] even though no solid evidence is available supporting this suggestion.

Clear indications, the clinical approach

Pancreatic indications

The procedure is mostly indicated to aid in the intraoperative localization of small pancreatic tumors,

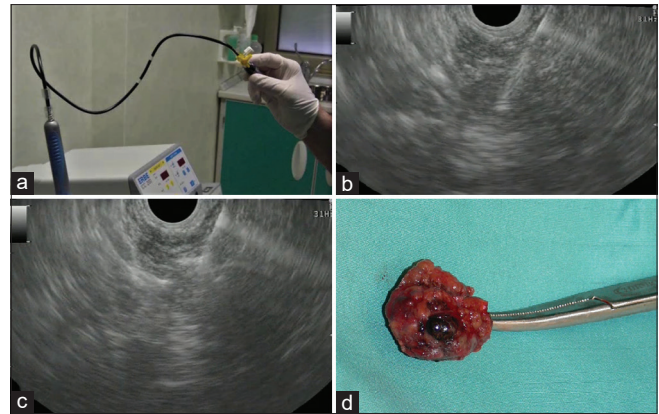


Figure 2. EUS-guided tattooing of a small pancreatic insulinoma before surgical resection: (a) Priming of the 22-gauge EUS-FNA needle with the marking solution (Spot[®]; GI supply, Camp Hill, PA, USA); (b) EUS-guided puncture of the lesion; (c) hyperechoic spot appearing at the tip of the needle by injection of the sterile carbon-based ink initially inside the lesion, injection which is continued while withdrawing the needle; (d) resection specimen harboring the black discoloration determined by tattooing; its appearance at the surface of the lesion helped the surgeon find it intraoperatively and resect it laparoscopically

especially when the laparoscopic approach is used. In this case, the surgeon loses the capability of palpating the organ and of finding small lesions; thus, EUS marking is used to create a recognizable spot that can be seen through the serosa covering the pancreatic parenchyma.

Possible other indications

Other possible indications could be marking of subepithelial lesions of the gastrointestinal tract (such as gastrointestinal stromal tumors), with exophytic development for surgical identification and resection, or marking of lymph nodes for intraoperative identification and harvest. However, none of these possible indications has been reported so far.

Pros

The technique is simple, easy to perform even during the same session of EUS-guided tissue acquisition, and cheap. Using carbon-based solutions, EUS-FNT can be performed at the time of initial EUS evaluation, without any concern about the time span between the tattooing procedure and the surgical intervention, thus avoiding the costs and risks associated with repeating the EUS-FNT procedure.^[16]

Preoperative marking of small tumors is of great value in assisting in their localization during surgery, particularly during the laparoscopic approach.^[25] Indeed, up to two-thirds of pancreatic insulinomas measure <2 cm, and up to a quarter of them have a

diameter of <1 cm.^[8] Because of these characteristics, up to one-fifth of insulinomas cannot be localized intraoperatively by palpation only,^[18] in particular, if located in the pancreatic head.^[12] Thus, EUS is not only superior to other methods in the identification of pancreatic insulinomas and of other pancreatic neuroendocrine neoplasms, when preoperative transabdominal ultrasound, computed tomography, and MRI scans failed,^[26-29] but also provides a method for easier intraoperative recognition by performing EUS-FNT. In other cases, EUS-FNT should be used as a landmark for performing limited surgical resection (by laparoscopy) or tumor enucleation,^[15] since preservation of pancreatic parenchyma is of utmost importance to decrease the risk for long-term endocrine and exocrine pancreatic insufficiency, especially after distal pancreatectomy, when new-onset diabetes mellitus is observed in from 8% to 23% of patients.^[30,31] Moreover, utilization of EUS-FNT for preoperative delineation of small pancreatic tumors results in a decreased operative time and in lower re-operation rates, due to the inappropriate primary resection of the lesion.^[17]

Cons

There are limited studies that have evaluated the performance of EUS-FNT in terms of applicability and clinical effectiveness in a meaningful number of patients and with proper study design. The limited experience accumulated so far suggests that the use of the above-mentioned solutions for marking, when utilized in a proper manner, is not associated with significant AEs. However, although the clinically apparent AEs are so far nil in the reported cases, in two of the patients, mild local pancreatic inflammatory changes were noted at surgery performed very soon after EUS-FNT.^[16,17] Thus, since EUS-FNA of pancreatic lesions is associated with a small risk of acute pancreatitis (0.9%) and infection (0.9%),^[32] and India ink colonic endoscopic tattooing has been reported to rarely cause infectious complications (0.22%),^[33,34] one should expect a small rate of AEs associated with this procedure. Moreover, the choice of the proper marking solution and the quantity needed for tattooing have not been clarified yet.

CONCLUSIONS

EUS-FNT is a safe and effective procedure to provide intraoperative identification of small pancreatic lesions, with the potential to increase their recognition, reduce

operative time by helping surgeons to plan in advance pancreatic resections, achieve negative resection margins, and spare normal pancreatic parenchyma. Large prospective multicenter randomized studies are needed to clearly demonstrate the role of EUS-FNT in all patients undergoing surgical resection of small pancreatic lesions, as well as to assess its efficacy in reducing the incidence of exocrine/endocrine postoperative pancreatic insufficiency. Other applications for EUS-FNT are awaited.

Financial support and sponsorship

Nil.

Conflicts of interest

There are no conflicts of interest.

REFERENCES

- Atkinson NS, Bryant RV, Dong Y, et al. How to perform gastrointestinal ultrasound: Anatomy and normal findings. *World J Gastroenterol* 2017;23:6931-41.
- Atkinson NS, Bryant RV, Dong Y, et al. WFUMB position paper. Learning gastrointestinal ultrasound: Theory and practice. *Ultrasound Med Biol* 2016;42:2732-42.
- Dietrich CF, Averkiou M, Nielsen MB, et al. How to perform contrast-enhanced ultrasound (CEUS). *Ultrasound Int Open* 2018;4:E2-15.
- Dietrich CF, Bibby E, Jenssen C, et al. EUS elastography: How to do it? *Endosc Ultrasound* 2018;7:20-8.
- Dietrich CF, Barr RG, Farrokh A, et al. Strain elastography - How to do it? *Ultrasound Int Open* 2017;3:E137-49.
- Dietrich CF, Arcidiacono PG, Braden B, et al. What should be known prior to performing EUS? *Endoscopic ultrasound* 2019;8:3-16.
- Dietrich CF, Arcidiacono PG, Braden B, et al. What should be known prior to performing EUS exams? (Part II). *Endosc Ultrasound* 2019;8:360-9.
- Gress FG, Barawi M, Kim D, et al. Preoperative localization of a neuroendocrine tumor of the pancreas with EUS-guided fine needle tattooing. *Gastrointest Endosc* 2002;55:594-7.
- Jaroszewski DE, Schlinkert RT, Thompson GB, et al. Laparoscopic localization and resection of insulinomas. *Arch Surg* 2004;139:270-4.
- Ayav A, Bresler L, Brunaud L, et al. Laparoscopic approach for solitary insulinoma: A multicentre study. *Langenbeck's Arch Surg* 2005;390:134-40.
- Mabrut JY, Fernandez-Cruz L, Azagra JS, et al. Laparoscopic pancreatic resection: Results of a multicenter European study of 127 patients. *Surgery* 2005;137:597-605.
- Nikfarjam M, Warshaw AL, Axelrod L, et al. Improved contemporary surgical management of insulinomas: A 25-year experience at the Massachusetts general hospital. *Ann Surg* 2008;247:165-72.
- Zografos GN, Stathopoulou A, Mitropapas G, et al. Preoperative imaging and localization of small sized insulinoma with EUS-guided fine needle tattooing: A case report. *Hormones (Athens)* 2005;4:111-6.
- Ashida R, Yamao K, Okubo K, et al. Indocyanine green is an ideal dye for endoscopic ultrasound-guided fine-needle tattooing of pancreatic tumors. *Endoscopy* 2006;38:190-2.
- Farrell JJ, Sherrod A, Parekh D. EUS-guided fine-needle tattooing for preoperative localization of early pancreatic adenocarcinoma. *Gastrointest Endosc* 2009;69:176-7.
- Lennon AM, Newman N, Makary MA, et al. EUS-guided tattooing before laparoscopic distal pancreatic resection (with video). *Gastrointest Endosc* 2010;72:1089-94.
- Newman NA, Lennon AM, Edil BH, et al. Preoperative endoscopic

- tattooing of pancreatic body and tail lesions decreases operative time for laparoscopic distal pancreatectomy. *Surgery* 2010;148:371-7.
18. Rodriguez A, Canto MI, Makary MA. Endoscopic localization and tattooing of a proinsulinoma for minimally invasive resection. *Pancreas* 2011;40:474-7.
 19. Leelasinjaroen P, Manatsathit W, Berri R, et al. Role of preoperative endoscopic ultrasound-guided fine-needle tattooing of a pancreatic head insulinoma. *World J Gastrointest Endosc* 2014;6:506-9.
 20. Okuzono T, Kanno Y, Nakahori M, et al. Preoperative endoscopic ultrasonography-guided tattooing of the pancreas with a minuscule amount of marking solution using a newly designed injector. *Digestive Endosc* 2016;28:744-8.
 21. Ginsberg GG, Barkun AN, Bosco JJ, et al. Endoscopic tattooing: February 2002. *Gastrointest Endosc* 2002;55:811-4.
 22. Available from: https://en.wikipedia.org/wiki/India_ink. [last accessed on 2020 Jan 30].
 23. Veitch AM, Vanbiervliet G, Gershlick AH, et al. Endoscopy in patients on antiplatelet or anticoagulant therapy, including direct oral anticoagulants: British Society of Gastroenterology (BSG) and European Society of Gastrointestinal Endoscopy (ESGE) guidelines. *Endoscopy* 2016;48:c1.
 24. Jenssen C, Fusaroli P, Hocke M, et al. EFSUMB guidelines on interventional ultrasound (INVUS). Part IV – EUS-guided interventions: General aspects and EUS-guided sampling (long version). *Ultraschall Med* 2016;37:E33-76.
 25. Briggs CD, Mann CD, Irving GR, et al. Systematic review of minimally invasive pancreatic resection. *J Gastrointest Surg* 2009;13:1129-37.
 26. Rosch T, Lightdale CJ, Botet JF, et al. Localization of pancreatic endocrine tumors by endoscopic ultrasonography. *New England J Med* 1992;326:1721-6.
 27. James PD, Tsolakis AV, Zhang M, et al. Incremental benefit of preoperative EUS for the detection of pancreatic neuroendocrine tumors: A meta-analysis. *Gastrointest Endosc* 2015;81:848-560.
 28. van Asselt SJ, Brouwers AH, van Dullemen HM, et al. EUS is superior for detection of pancreatic lesions compared with standard imaging in patients with multiple endocrine neoplasia type 1. *Gastrointest Endosc* 2015;81:159-6700.
 29. Kann PH. Is endoscopic ultrasonography more sensitive than magnetic resonance imaging in detecting and localizing pancreatic neuroendocrine tumors? *Rev Endocr Metab Disord* 2018;19:133-7.
 30. Hutchins RR, Hart RS, Pacifico M, et al. Long-term results of distal pancreatectomy for chronic pancreatitis in 90 patients. *Ann Surg* 2002;236:612-8.
 31. Lillemoe KD, Kaushal S, Cameron JL, et al. Distal pancreatectomy: Indications and outcomes in 235 patients. *Ann Surg* 1999;229:693-8.
 32. Eloubeidi MA, Tamhane A, Varadarajulu S, et al. Frequency of major complications after EUS-guided FNA of solid pancreatic masses: A prospective evaluation. *Gastrointest Endosc* 2006;63:622-9.
 33. Nizam R, Siddiqi N, Landas SK, et al. Colonic tattooing with India ink: Benefits, risks, and alternatives. *Am J Gastroenterol* 1996;91:1804-8.
 34. Alba LM, Pandya PK, Clarkston WK. Rectus muscle abscess associated with endoscopic tattooing of the colon with India ink. *Gastrointest Endosc* 2000;52:557-8.