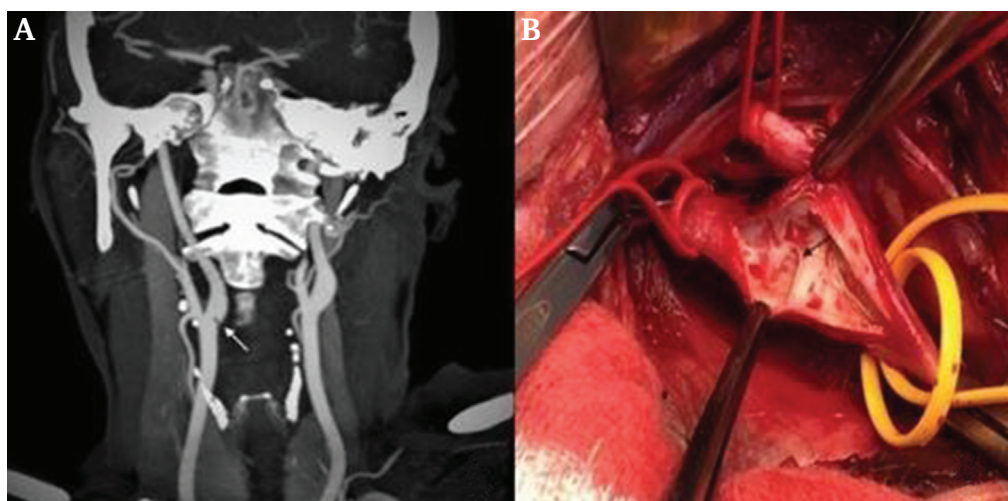


IMAGE

Carotid Web in a Patient with a Recurrent Stroke

A 43 year old female smoker, suffered a left hemiparesis secondary to acute occlusion of the right middle cerebral artery and underwent mechanical thrombectomy with a good result. Four years later, she suffered a similar recurrent episode. Computed tomography angiography found an occlusive thrombus at the distal M1 segment and a spiculated septum in the lumen of the right carotid sinus, which was compatible with a carotid web (Figure 1A, white arrow). Mechanical thrombectomy was performed again, with

a good clinical and angiographic result. Other causes of stroke were ruled out. The patient underwent resection of a membrane on the posterior wall of the carotid bulb (Figure 1B, black arrow). No thrombus was found along the surface of the web and the rest of the carotid artery looked normal. Histopathology showed a thickening of the elastic fibres of the arterial intima (fibromuscular dysplasia intimal variant). The post-operative course was uneventful. The patient was discharged on long term clopidogrel 75 mg daily.



Martin Zapater^{*}, Jorge V. Rico
*Complejo Hospitalario Universitario A Coruña, Coruña,
Spain*

**Corresponding author.
Email-address: martin.zapater.salgueiro@sergas.es (Martin
Zapater)*

© 2021 The Authors. Published by Elsevier Ltd on behalf of European Society for Vascular Surgery. This is an open access article under the CC BY-NC-ND license (<http://creativecommons.org/licenses/by-nc-nd/4.0/>).

<https://doi.org/10.1016/j.ejvsf.2021.04.003>